

## ARTICLES

# A juvenile early hominin skeleton from Dikika, Ethiopia

Zeresenay Alemseged<sup>1</sup>, Fred Spoor<sup>2</sup>, William H. Kimbel<sup>3</sup>, René Bobe<sup>4</sup>, Denis Geraads<sup>5</sup>, Denné Reed<sup>6</sup>  
& Jonathan G. Wynn<sup>7†</sup>

**Understanding changes in ontogenetic development is central to the study of human evolution. With the exception of Neanderthals, the growth patterns of fossil hominins have not been studied comprehensively because the fossil record currently lacks specimens that document both cranial and postcranial development at young ontogenetic stages. Here we describe a well-preserved 3.3-million-year-old juvenile partial skeleton of *Australopithecus afarensis* discovered in the Dikika research area of Ethiopia. The skull of the approximately three-year-old presumed female shows that most features diagnostic of the species are evident even at this early stage of development. The find includes many previously unknown skeletal elements from the Pliocene hominin record, including a hyoid bone that has a typical African ape morphology. The foot and other evidence from the lower limb provide clear evidence for bipedal locomotion, but the gorilla-like scapula and long and curved manual phalanges raise new questions about the importance of arboreal behaviour in the *A. afarensis* locomotor repertoire.**

The skull and associated partial skeleton (DIK-1-1) were recovered at Locality DIK-1 of the Dikika research area during the 2000, 2002 and 2003 field seasons by the Dikika Research Project (DRP)<sup>1</sup> led by Z.A. It derives from sediments of the Sidi Hakoma Member of the Hadar Formation, which span the age of 3.31 to 3.35 million years on the basis of stratigraphic scaling and known chronostratigraphy<sup>2</sup>. Sandstones that yielded the specimen were deposited on a subaerial delta plain. This depositional setting, combined with the remarkable preservation of many articulated faunal remains lacking evidence of preburial weathering, most likely indicates that the juvenile hominin was buried as an intact corpse shortly after death during a major flood event.

The new find represents a young individual. The skull and numerous elements of the articulated axial skeleton were recovered in a block of sandstone matrix (Fig. 1a–f), and additional postcranial parts were found separately (Table 1). As originally recovered, the skull was devoid of covering matrix except for the midface, left temporal bone and the cranial base, but most of the postcranium was covered by matrix (Fig. 1a). Preparation of the main block has been undertaken for the past five years, and this has progressed to a point where much of the specimen's key morphology can be studied. However, fully exposing and isolating the many postcranial elements is a complex task that will take several more years to complete (Fig. 1b, c).

The cranium is intact except for parts of the frontal squama and significant parts of both parietals, which have broken away to reveal the complete natural brain endocast (Fig. 1d). The back of the calvaria is slightly distorted, pushing the nuchal region forward (Fig. 1f). The mandible is complete and is still in articulation with the cranium, but has slipped anteriorly by a few millimetres, which may have played a role in displacing the right zygomaticomaxillary area as well as the nasal and left supraorbital regions in the same

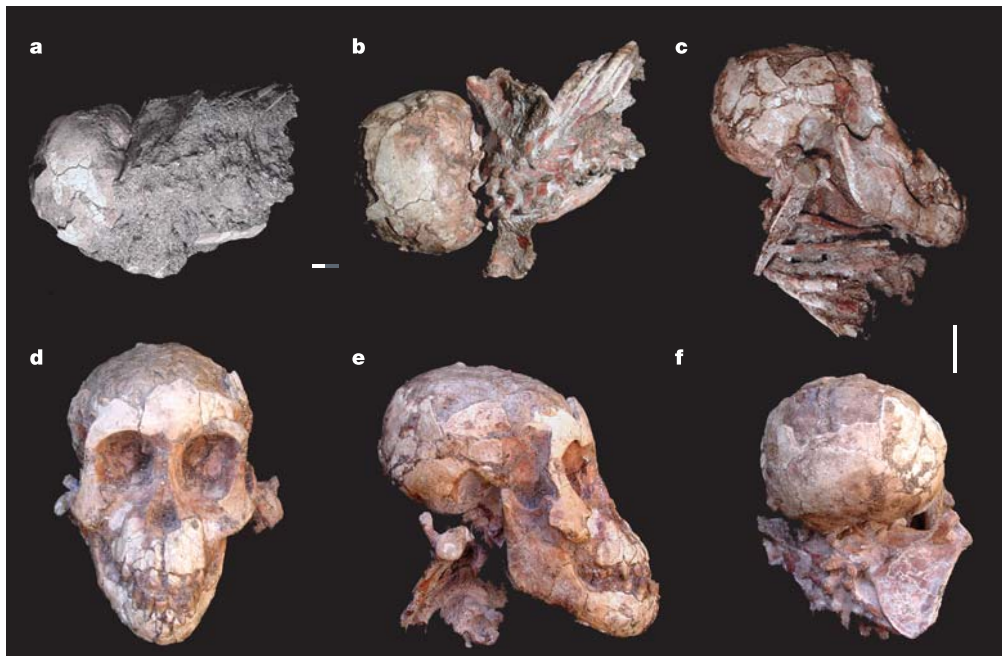
direction (Fig. 1e). All deciduous teeth are preserved, except for the left lower incisor crowns (Fig. 3a). The hyoid bone is preserved beneath the palate (Fig. 3b).

The articulated postcranial elements in the primary sandstone block include both scapulae and clavicles, the cervical, thoracic and the first two lumbar vertebrae, and many ribs. They are displaced from their original anatomical positions, and are compressed superiorly under the cranial base and the palate, making preparation difficult (Fig. 1b, c). Elements of the limbs recovered separately consist of a distal fragment of the right humerus including a tiny unfused medial epicondyle (Fig. 2a), and one ray of the hand containing proximal, intermediate and distal phalanges, along with the proximal phalanx from an adjacent ray (Fig. 3c). The distal femora and proximal tibiae include significant portions of their shafts (of which approximately two-thirds is preserved), and both patellae are present (Fig. 2b, c). The distal ends of the left tibia and fibula, including their unfused epiphyses, are still articulated with the partly matrix-covered foot (Fig. 2d). The latter lacks only its phalanges and the distal-most ends of the metatarsals.

## Description and comparison

**Age and sex of DIK-1-1.** All deciduous teeth were erupted and in occlusion at death. Computed tomography (CT) scanning reveals unerupted, but fully formed, first molar crowns with clear evidence of root development, as well as partial crowns of the second molars (Fig. 3a). Premolar and permanent canine and incisor crowns are also present, with the fourth premolars being least completed. On the basis of this stage of dental development, and using an African ape model<sup>3</sup>, the age at death of DIK-1-1 is estimated as about three years. Assuming an attribution to *Australopithecus afarensis* (see below), CT-based measurements of the fully formed permanent tooth crowns suggest that the specimen is female (Table 2, Supplementary Note S1).

<sup>1</sup>Department of Human Evolution, Max-Planck-Institute for Evolutionary Anthropology, Deutscher Platz 6, 04103 Leipzig, Germany. <sup>2</sup>Department of Anatomy and Developmental Biology, University College London, Gower Street, London WC1E 6BT, UK. <sup>3</sup>Institute of Human Origins, School of Human Evolution and Social Change, PO Box 874101, Arizona State University, Tempe, Arizona 85287-4101, USA. <sup>4</sup>Department of Anthropology, University of Georgia, Athens, Georgia 30602-1619, USA. <sup>5</sup>CNRS UPR 2147, 44 rue de l'Amiral Mouchez, F-75014 Paris, France. <sup>6</sup>Department of Anthropology, University of Texas at Austin, Austin, Texas 78712, USA. <sup>7</sup>School of Geography and Geosciences, University of St Andrews, St Andrews KY16 9AL, Scotland, UK. †Present address: Department of Geology, University of South Florida, Tampa, Florida 33620, USA.



**Figure 1 | The DIK-1-1 juvenile skull and partial skeleton.** **a, b**, Dorsal and inferior view as discovered (**a**) and after partial preparation (**b**). **c**, Lateral view after partial preparation showing the scapula and many ribs. **d–f**, Anterior (**d**), lateral (**e**) and posterior (**f**) views. Scale bars, 2 cm (**a, b** and **c–f**).

**Comparative skull morphology.** Size and proportions of the DIK-1-1 face resemble those of the juvenile specimens A.L. 333-105 and Taung, assigned to *A. afarensis* and *A. africanus*, respectively (Table 3). In overall prognathism, it is close to both juvenile and adult specimens of these two species (Table 3, angle sellion–prosthion to alveolar margin). In lateral view, the facial profile forms a relatively straight line from sellion to nasospinale to prosthion (Fig. 1e), whereas in adult *A. afarensis* (for example, A.L. 417-1, 444-2) the midfacial outline is distinctly more vertical than the more prognathic subnasal clivus (Table 3, angle sellion–nasospinale–prosthion). In contrast, older *A. africanus* individuals (Sts 5, 52, 71) have a straighter facial profile than the Taung juvenile. It is not clear if this represents different patterns of facial maturation, as all the variation subsumed by these australopith specimens can be accommodated within the range of intraspecific variation of African apes (Supplementary Note S2).

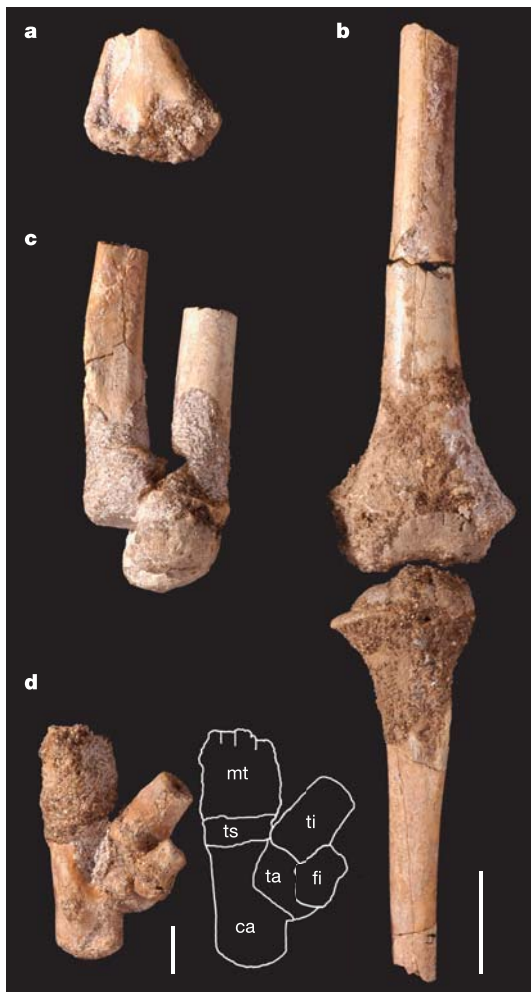In the detailed morphology of the face, DIK-1-1 resembles *A. afarensis*<sup>4</sup> and differs from *A. africanus*, including Taung<sup>5</sup>. Its nasoalveolar clivus is biconvex, whereas it is flatter in *A. africanus*, particularly mediolaterally. The nasal aperture is narrow, as in other juvenile *A. afarensis* such as A.L. 333-86, particularly compared with its height<sup>6</sup>. The canine juga in DIK-1-1 are placed more laterally than in *A. africanus* and they are topographically independent of the sharp-rimmed nasal aperture, as in A.L. 333-105. In contrast to

Taung, no incipient anterior pillars are present and the frontal process of the maxilla is flat lateral to the aperture<sup>7</sup>. The nasal bones of DIK-1-1 are tall, narrow and hourglass-shaped, with nasion positioned well above the nasomaxillary and frontomaxillary sutures. This morphology is seen in A.L. 333-105 and in many apes<sup>6</sup>, but differs from the shorter and broader nasal bones of *A. africanus*. DIK-1-1 has only a slightly convex glabellar region, unlike the more prominent development in Taung. Most of the basicranium is still covered with matrix and displaced axial elements, but the exposed nuchal plane and CT scans suggest that the foramen magnum is located more anteriorly than in apes of comparable dental age<sup>8,9</sup>.

Preliminary volume measurements of the preserved endocast of DIK-1-1 from CT scans yield a value of 235 cm<sup>3</sup>. However, this endocranial volume (EV) underestimates the true value because of the minor deformation of the occipital region, and a few areas of the cranial base where the bone–matrix interface is unclear. To provide an alternative estimate, we calculated the correlation between the EV and the combined endocranial breadth and midsagittal arc for an ontogenetic series of *Pan troglodytes* and *Gorilla gorilla*. Using the regression equations, the EV of DIK-1-1 was estimated as 275 to 330 cm<sup>3</sup> (Supplementary Note S3). This is not unlike the volume evident in *P. troglodytes* of a comparable dental age of three years (Supplementary Note S4a). DIK-1-1 would have completed between ~65 and 88 per cent of an average EV of 375 to 425 cm<sup>3</sup> estimated for

**Table 1 | Dikika fossil hominin specimen discoveries**

| Specimen number | Collection date  | Element  | Found by         |
|-----------------|------------------|--|------------------|
| DIK-1-1a        | 10 December 2000 | Skull and partial skeleton                     | T. Gebreselassie |
| DIK-1-1b        | 30 December 2000 | Frontal fragment                               | R. Abe           |
| DIK-1-1c        | 30 December 2000 | Left scapula fragment plus ribs                | Z.A.             |
| DIK-1-1d        | 19 January 2002  | Manual phalanges                               | Z.A.             |
| DIK-1-1e        | 25 January 2002  | Left proximal tibia                            | Z.A.             |
| DIK-1-1f        | 21 January 2002  | Left foot                                      | D.G.             |
| DIK-1-1 g       | 26 January 2003  | Right distal femur, patella and proximal tibia | D.R.             |
| DIK-1-1i        | 4 February 2003  | Right humerus                                  | Z.A.             |
| DIK-1-1j        | 8 February 2003  | Left distal femur and patella                  | A. Ahmed         |
| DIK-1-1 h       | 17 November 2003 | Left tibia fragment                            | W. Obsie         |
| DIK1-1k         | 3 December 2003  | Left femur fragment                            | W. Obsie         |
| -               | -                | Many rib fragments                             | Team             |



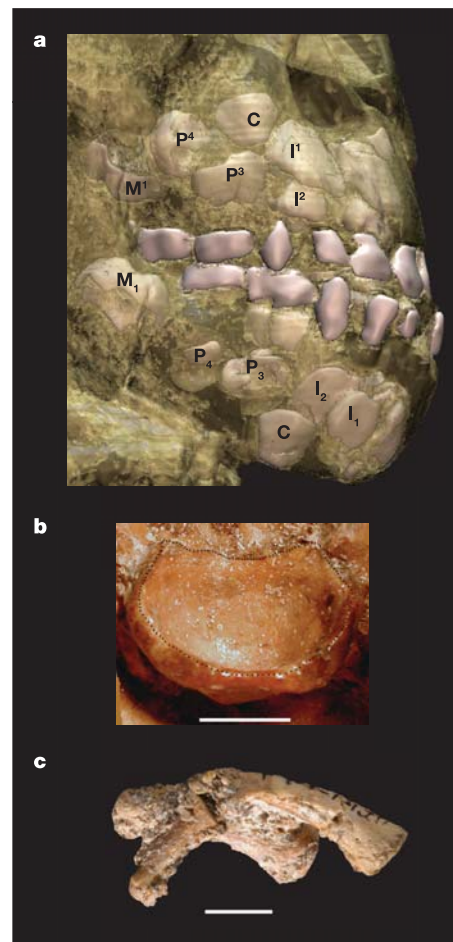
**Figure 2 | The DIK-1-1 juvenile postcrania.** **a**, Right distal humerus. **b**, Left distal femur and proximal tibia. **c**, Right distal femur and proximal tibia in a flexed position, connected by matrix, with the tibial and femoral diaphyses pointing upwards. **d**, Left foot and its outline including metatarsals (mt), distal tibia (ti), distal fibula (fi), talus (ta), calcaneus (ca) and tarsals (ts). Scale bars, 1 cm for the foot (**d**) and 2 cm for the limb bones (**a–c**).

adult female *A. afarensis*<sup>10</sup>. This proportional endocranial volume, and that of A.L. 333-105, overlaps with the range of variation of both modern humans and African apes (Supplementary Note S4b).

The current position of the hyoid bone beneath the palate precludes a comprehensive analysis of its morphology (Fig. 3b), but some diagnostic features can be observed and measured. It is most similar to that of juvenile African apes, and unlike that of modern humans<sup>11,12</sup>. The exposed greater horn is slender, and the body is expanded anteriorly, forming a bulla that is deep relative to its breadth and height (Fig. 4a, Supplementary Note S5).

The mandible of DIK-1-1 closely resembles juvenile *A. afarensis* specimens, especially A.L. 333-43 (ref. 13). As in adult Hadar specimens of *A. afarensis*, the external symphyseal contour is bulbous and fairly vertical, distinguishing it from Laetoli juvenile and adult conspecifics, which resemble the more retreating, posteroinferiorly inclined condition seen in *A. anamensis*<sup>14,15</sup>. As in A.L. 333-43 and A.L. 333n-1, a single anterosuperiorly opening mental foramen is located just below midcorpus at the level of the first deciduous molar<sup>16</sup>.

The deciduous upper central incisors are larger than the lateral ones (Table 2), and their overall morphology is similar to that of juvenile apes. In labial view, they are fan-shaped, rather than cylindrical as in Taung, although damage has altered the original



**Figure 3 | The DIK-1-1 dentition, hyoid bone and manual phalanges.**

**a**, Three-dimensional reconstruction of CT images of the maxilla and mandible in occlusion showing the deciduous and permanent dentition. Bony elements of the skull have been made translucent to make the dentition visible, and only permanent teeth of the right side are labelled. **b**, Inferoposterior view of the body of the hyoid bone sitting on the palate with the anterior bulla facing inferiorly. Dark dots indicate the rim of the body. **c**, Hand phalanges: one ray of the hand containing the proximal and intermediate phalanx is on top; beneath this is the proximal phalanx from an adjacent ray. The three phalanges are connected by matrix. Scale bars, 5 mm (**b, c**).

shape of the latter. Crowns of the lower incisors are small and similar in size. The deciduous upper canines have diamond-shaped crowns in labial view, similar to Hadar specimen A.L. 333-99 (ref. 17). In labial view, the lower canine crown is high, pointed and mesiodistally convex; it projects above the occlusal level of the incisors and deciduous molars. The protoconid of the dm1 (first deciduous molar) is larger than the hypoconid, as in A.L. 333-43; the buccal face slopes towards the protoconid tip and is ringed by a basal bulge<sup>18</sup>. These features distinguish the DIK-1-1 dm1 from those of great apes, which are buccolingually compressed and almost unicuspid, with the protoconid dominating the occlusal view. As for Hadar specimens, the DIK-1-1 deciduous canines and molars do not show the more ape-like morphology encountered in *A. anamensis* and *A. ramidus*<sup>19,20</sup>. On the basis of the many craniodental similarities to juvenile and adult Hadar specimens, we attribute DIK-1-1 to *A. afarensis*.

**Postcranium of DIK-1-1.** Most bipedal features seen in *A. afarensis* specimens are observed on the lower limb and foot of DIK-1-1 (ref. 21). Overall, the tibiae—with their transversely expanded shaft beneath the tibial plateau—are similar to that of the juvenile A.L. 333-39 (ref. 22), but have a sharper anterior border also shown by modern



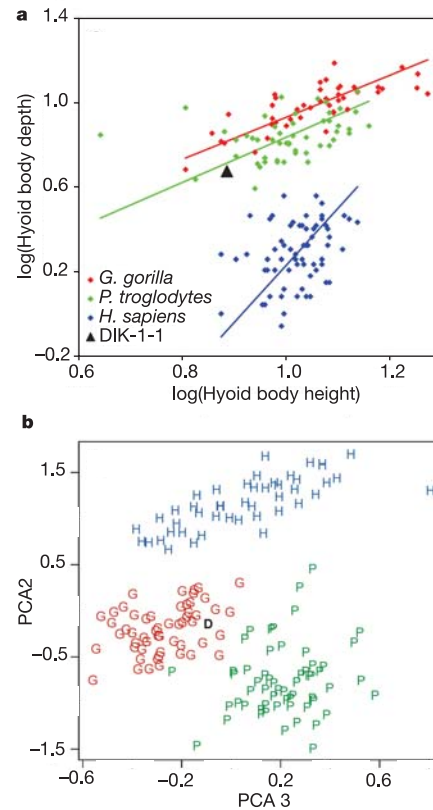
**Table 2 | Dental measurements for DIK-1-1**

|                        | MD        | BL and LL   | CH (buccal) |
|------------------------|-----------|-------------|-------------|
| <b>Upper permanent</b> |           |             |             |
| I <sup>1</sup>         | 10.2      | >7.7        | >11.5       |
| I <sup>2</sup>         | 7.0       | >5.3        | >7.3        |
| C                      | 9.5       | >7.5        | >9.2        |
| P <sup>3</sup>         | 8.5       | >11.2       | -           |
| P <sup>4</sup>         | ≥8.2      | >10.2       | -           |
| M <sup>1</sup>         | 11.5      | 12.4*/12.5† | -           |
| <b>Lower permanent</b> |           |             |             |
| I <sub>1</sub>         | 6.5       | >4.7        | >10         |
| I <sub>2</sub>         | 7.2       | >5.7        | >9.3        |
| C                      | 8.3       | >6          | >9.5        |
| P <sub>3</sub>         | 8.9*/9.2† | 10.3*/9.8†  | -           |
| M <sub>1</sub>         | 12.3      | 11.7        | -           |

Values preceded by “>” represent a minimum size; crown possibly not fully formed locally. MD, mesiodistal; BL, buccolingual; LL, labiolingual; CH, crown height. \*Method after ref. 18. †Method after ref. 36.

humans (Fig. 2b). As in modern humans, the tibialis anterior muscle originated anterior to the interosseous ridge and occupied the lateral side of the tibial shaft, extending the sharp anterior border. The tibialis posterior muscle occupied the lateral aspect of the posterior part of the shaft. Similar to humans, the lateral upper part of the shaft is rather concave, particularly just below the condyles, and becomes convex more distally. Also, the cross-section of the shaft changes from triangular proximally to oval at its distal-most preserved part. The bicondylar angle and symmetrical condyles are additional features previously known in *A. afarensis*. The medial and lateral borders of the talar trochlea are similar in curvature and height (Fig. 2d), and the partly exposed medial side of the talar body is vertical in surface orientation (Fig. 2d). The calcaneus of DIK-1-1 is robust, as in humans, and its distal part is mediolaterally wider in relation to its dorsoplantar dimension compared with that of *Pan*.

The shape of the scapula resembles the scapulae of juvenile and adult gorillas (Fig. 5, Supplementary Note S6). In contrast, modern humans at a similar age have a wider infraspinous fossa and a more laterally facing glenoid fossa, with a correspondingly horizontal spine orientation, whereas chimpanzees tend to have a narrower infraspinous fossa and a more superiorly facing glenoid fossa with a corresponding spine orientation. DIK-1-1 does contrast with gorillas in its narrower supraspinous fossa and less inclined spine, and in these features it is intermediate between African apes and humans. Nevertheless, comparing supraspinous and infraspinous fossa breadths still groups DIK-1-1 more closely with gorilla than with modern humans (Supplementary Note S6e, h). These affinities are also shown in a principal components analysis of 11 linear morphometric measurements (Fig. 4b, Supplementary Note S6i). Finally, the distal humerus preserves a deep and wide olecranon fossa and the



**Figure 4 | The DIK-1-1 hyoid and scapula morphology.** **a**, Bivariate plot of the posterior depth of the hyoid body against its height (in mm). The values are logged because the relationship is allometric in modern humans (Supplementary Note S5c). **b**, Principal components analysis (PCA) of 11 linear morphometric measurements of the scapula of DIK-1-1 (D), *G. gorilla* (G), *P. troglodytes* (P) and *Homo sapiens* (H). Comparative samples include juveniles and adults (Supplementary Note S6i).

manual phalanges are curved and long, as noted previously for *A. afarensis* (Fig. 3c).

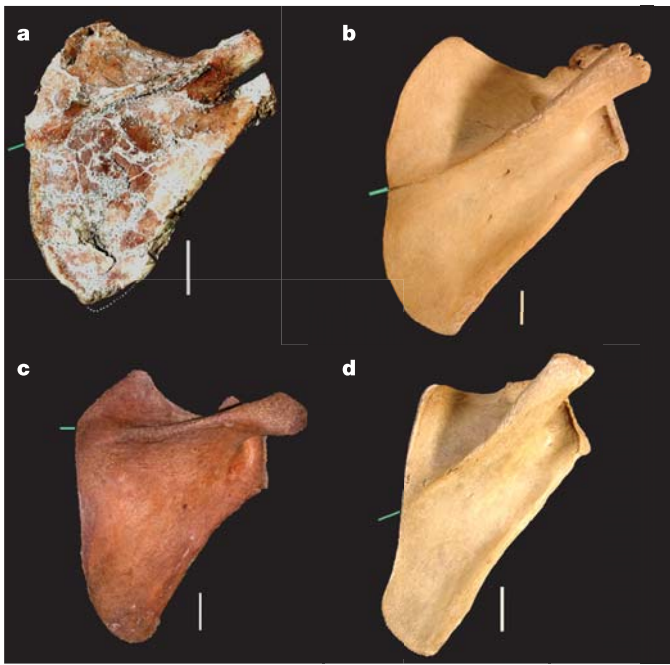
**Discussion**

The DIK-1-1 skeleton is unmatched in the early hominin fossil record not only because of its completeness, but because it reveals previously unknown morphology and provides a comprehensive cranial and postcranial record of a juvenile australopith. As it concerns a single individual, rather than isolated finds of variable age assumed to represent a single species, it will now be possible to

**Table 3 | Hominin cranial measurements**

|  | <i>A. afarensis</i> |              |                    | <i>A. africanus</i> |               |
|--|---------------------|--------------|--------------------|---------------------|---------------|
|  | DIK-1-1a            | A.L. 333-105 | A.L. 417-1*, 444-2 | Taung               | Sts 5, 52, 71 |
| <b>Linear dimension (mm)</b>                     |                     |              |                    |                     |               |
| Glabella-opisthocranion                          | >98                 | NP           | -                  | ~127                | -             |
| Prosthion-opisthocranion                         | >133                | NP           | -                  | ~144                | -             |
| Maximum vault breadth                            | 90                  | NP           | -                  | ~95                 | -             |
| Nasion-nasospinale (na-ns)                       | 32                  | 37           | -                  | 33                  | -             |
| Nasospinale-prosthion (ns-pr)                    | 17                  | 17           | -                  | 18                  | -             |
| Bimaxillary breadth (zm-zm)                      | 60                  | 65           | -                  | 65                  | -             |
| (na-ns/zm-zm) × 100                              | 53                  | 57           | -                  | 51                  | -             |
| (ns-pr/zm-zm) × 100                              | 28                  | 26           | -                  | 28                  | -             |
| <b>Angle (degrees)</b>                           |                     |              |                    |                     |               |
| Sellion-prosthion to post-canine alveolar margin | 62                  | 59           | 55-58              | 64                  | 60-61         |
| Sellion-nasospinale-prosthion                    | 155                 | 149          | 144-147            | 140                 | 148-149       |

Values preceded by “>” represent minimum values for DIK-1-1 because of occipital deformation. Values preceded by “~” are estimates based on the endocast<sup>37</sup>. NP, not preserved. \*Sellion of A.L. 417-1 estimated.



**Figure 5 | Right scapulae, dorsal view.** **a**, DIK-1-1 (*A. afarensis*). Dotted line around the inferior angle estimates the shape of the broken piece in that region, on the basis of the preserved part on the left scapula of the same individual. **b**, *G. gorilla*. **c**, *H. sapiens*. **d**, *P. troglodytes*. In each, the short green line shows the point where the spine meets the medial border of the scapula. All are juveniles of about the same dental age and oriented with the line connecting the superior and inferior angles perpendicular to the horizontal. Scale bars, 1 cm (**a–d**).

study early hominin ontogenetic development by integrating directly associated evidence from the dentition, brain and postcranium. Its attribution to *A. afarensis*, and the adult context in which it thus should be considered, is unambiguous because the diagnostic facial morphology of this species is evident even at this juvenile stage. Substantial change in facial shape is mainly anticipated in the subnasal region, probably in association with the eruption of the anterior teeth.

Brain growth in DIK-1-1—expressed as the percentage of mean adult EV completed—is at a developmental stage when the patterns of African apes and modern humans overlap substantially and, consequently, the fossil cannot be grouped specifically with either (Supplementary Note S4b). Nevertheless, it is intriguing that in this proportional EV, both DIK-1-1 and A.L. 333-105 fall below the average rate of African apes, and are broadly more in line with the average rate in modern humans. In modern humans, the lower proportional EV rates are due to their large adult EV. However, in *A. afarensis*, with its adult EV values within the range of African apes, the lower proportional EV would have to imply slower absolute brain growth. The possibility of this phenomenon, known in platyrrhines<sup>23</sup>, warrants further investigation, but resolution may only come from the discovery of younger individuals, representing a stage when apes and humans show much less overlap in their patterns of brain development.

The hyoid of DIK-1-1 is only the second example in the hominin fossil record<sup>12</sup>, and this element was previously unknown for any species earlier than Neanderthals. Its similarities with *Pan* and *Gorilla* hyoids suggest that the bulla-shaped body is the primitive condition for African apes and humans, rather than the more shallow, bar-like body shown by modern humans and *Pongo*. The bulla-shaped body almost certainly reflects the presence of laryngeal air sacs characteristic of African apes<sup>24</sup>. However, the function of these structures is not well understood<sup>25</sup>.

The DIK-1-1 skeleton confirms the functional dichotomy of the body plan of *A. afarensis*: a more derived lower body adapted for bipedal locomotion, combined with an upper body that is, in many respects, ape-like. The functional interpretation of these features is highly debated, with some arguing that the upper limb features are non-functional retentions from a common ancestor only<sup>26–28</sup>, whereas others propose that they were preserved because *A. afarensis* maintained, to some degree, an arboreal component in its locomotor repertoire<sup>29–32</sup>. Now that the scapula of this species can be examined in full for the first time, it is unexpected to find the strongest similarities with *Gorilla*, an animal in which weight-bearing and terrestrial knuckle-walking predominately characterize locomotor use of the forelimbs<sup>33</sup>. Problematic in the interpretation of these findings is that the diversity of scapula architecture among hominoid species is poorly understood from a functional perspective.

The superiorly facing glenoid fossa, noticed previously<sup>31</sup>, provides the most tantalizing suggestion that the structure and function of the upper body in *A. afarensis* was different from that of modern humans. It could indicate a superiorly positioned shoulder girdle, and possibly the absence of effective decoupling of head and trunk movements, typical of modern humans and their capability for endurance running<sup>34</sup>. The preserved clavicles and full cervical vertebral column of DIK-1-1 will bring new insights in this respect, pending a particularly difficult process of preparation to isolate these elements. One further clue in this context is that the semicircular system in DIK-1-1 is similar to that of African apes and *A. africanus* (Supplementary Note 7), and this has been associated with limited head decoupling and absence of fast and agile bipedal gaits<sup>35</sup>. If functionally relevant, the glenoid fossa orientation in DIK-1-1 could also point to frequent use of the arms above the head<sup>31</sup>, and the activity with which this would be most consistent is climbing. The apparent tendency towards a reduced attachment area of the supraspinous muscle could be seen as evidence for a diminishing role of the arms in such locomotor postures. The scapula morphology, together with forelimb features such as the long and curved manual phalanges of DIK-1-1, will raise new questions about the importance of arboreal behaviour in *A. afarensis*. After years of discussion, new data, and in particular the ability to reconstruct much of an entire body of a three-year-old *A. afarensis* child will bring important new evidence to bear on this debate.

Received 22 April; accepted 6 July 2006.

1. Alemseged, Z. *et al.* A new hominin from the Basal Member of the Hadar Formation, Dikika, and its geological context. *J. Hum. Evol.* **49**, 499–514 (2005).
2. Wynn, J. G. *et al.* Geological and palaeontological context of a Pliocene juvenile hominin at Dikika, Ethiopia. *Nature* doi:10.1038/nature05048 (this issue).
3. Dean, C. & Wood, B. A. Digital radiographic atlas of the great apes skull and dentition. in *Digital Archives of Human Paleobiology* (eds Bondioli, L. & Machiarelli, R.) CD-ROM Vol. 3 (Museo Nazionale Preistorico Etnografico “L. Pigorini”, Rome, 2003).
4. Kimbel, W. H., Rak, Y. & Johanson, D. C. *The Skull of Australopithecus afarensis* (Oxford Univ. Press, New York, 2004).
5. Dart, R. A. *Australopithecus africanus*: The man-ape of South Africa. *Nature* **115**, 195–199 (1925).
6. Kimbel, W. H., Johanson, D. C. & Coppens, Y. Pliocene hominid cranial remains from the Hadar Formation, Ethiopia. *Am. J. Phys. Anthropol.* **57**, 453–499 (1982).
7. Rak, Y. *The Australopithecine Face* (Academic, New York, 1983).
8. Schultz, A. H. The position of the occipital condyles and of the face relative to the skull base in primates. *Am. J. Phys. Anthropol.* **13**, 97–120 (1955).
9. Luboga, S. A. & Wood, B. A. Position and orientation of the foramen magnum in higher primates. *Am. J. Phys. Anthropol.* **81**, 67–76 (1990).
10. Holloway, R. L., Broadfield, D. C. & Yuan, M. S. *Brain Endocasts—The Paleoneurological Evidence*. *The Human Fossil Record* Vol. 3 (Wiley, New Jersey, 2004).
11. Clegg, M. *The Comparative Anatomy and Evolution of the Human Tract*. PhD thesis, Univ. College London (2001).
12. Arensburg, B. *et al.* A Middle Palaeolithic human hyoid bone. *Nature* **338**, 758–760 (1989).
13. White, T. D. & Johanson, D. C. Pliocene hominid mandibles from the Hadar Formation, Ethiopia: 1974–1977 collections. *Am. J. Phys. Anthropol.* **57**, 501–544 (1982).

14. Ward, C. V., Leakey, M. G. & Walker, A. Morphology of *Australopithecus anamensis* from Kanapoi and Allia Bay, Kenya. *J. Hum. Evol.* **41**, 255–368 (2001).
15. Kimbel, W. H. *et al.* Was *Australopithecus anamensis* ancestral to *A. afarensis*? A case of anagenesis in the Pliocene hominin fossil record. *J. Hum. Evol.* **51**, 134–152 (2006).
16. Johanson, D. C. The most primitive *Australopithecus*. in *Hominid Evolution: Past, Present and Future* (ed. Tobias, P. V.) 203–212 (Wiley, New York, 1985).
17. Johanson, D. C., White, T. D. & Coppens, Y. Dental remains from the Hadar Formation, Ethiopia: 1974–1977 collections. *Am. J. Phys. Anthropol.* **57**, 545–603 (1982).
18. White, T. D. New fossil hominids from Laetolil, Tanzania. *Am. J. Phys. Anthropol.* **46**, 197–230 (1977).
19. White, T. D., Suwa, G. & Asfaw, B. *Australopithecus ramidus*, a new species of early hominid from Aramis, Ethiopia. *Nature* **371**, 306–312 (1994).
20. Leakey, M. G., Feibel, C. S., McDougall, I., Ward, C. & Walker, A. New specimens and confirmation of an early age for *Australopithecus anamensis*. *Nature* **393**, 62–66 (1998).
21. Aiello, A. & Dean, C. *An Introduction to Human Evolutionary Anatomy* (Academic, London, 1990).
22. Lovejoy, O. C., Johanson, D. C. & Coppens, Y. Hominid lower limb bones recovered from the Hadar Formation: 1974–1977 collections. *Am. J. Phys. Anthropol.* **57**, 679–700 (1982).
23. Leigh, S. R. Brain growth, life history, and cognition in primate and human evolution. *Am. J. Primatol.* **62**, 139–164 (2004).
24. Avril, C. Kehlkopf und Kehlsack des Schimpansen (*Pan troglodytes*). *Gegenbaurs Morphol. Jahrb.* **105**, 74–129 (1963).
25. Hewitt, G., MacLarnon, A. & Jones, K. E. The functions of laryngeal air sacs in primates: a new hypothesis. *Folia Primatol. (Basel)* **73**, 70–94 (2002).
26. Lovejoy, C. O. The origin of man. *Science* **211**, 341–350 (1981).
27. Lovejoy, C. O. Evolution of human walking. *Sci. Am.* **259**, 118–125 (1988).
28. Latimer, B. Locomotor adaptations in *Australopithecus afarensis*: the issue of arboreality. in *Origine de la bipédie chez les Hominidés* (eds Senut, B. & Coppens, Y.) 169–176 (CNRS, Paris, 1991).
29. Senut, B. & Tardieu, C. Functional aspects of Plio-Pleistocene hominid limb bones: implications for taxonomy and phylogeny. in *Ancestors: The Hard Evidence* (ed. Delson, E.) 193–201 (Liss, New York, 1979).
30. Susman, R. L., Stern, J. T. & Jungers, W. L. Arboreality and bipedality in the Hadar hominids. *Folia Primatol. (Basel)* **43**, 113–156 (1984).
31. Stern, J. T. & Susman, R. L. The locomotor anatomy of *Australopithecus afarensis*. *Am. J. Phys. Anthropol.* **60**, 279–317 (1983).
32. Stern, J. T. & Susman, R. L. “Total morphological pattern” versus the “magic trait”: conflicting approaches to the study of early hominid bipedalism. in *Origine de la bipédie chez les Hominidés* (eds Senut, B. & Coppens, Y.) 99–112 (CNRS, Paris, 1991).
33. Richmond, B. G. & Strait, D. S. Evidence that humans evolved from a knuckle-walking ancestor. *Nature* **404**, 382–385 (2000).
34. Bramble, D. M. & Lieberman, D. E. Endurance running and the evolution of *Homo*. *Nature* **432**, 345–352 (2004).
35. Spoor, F., Wood, B. & Zonneveld, F. Implications of early hominid labyrinthine morphology for the evolution of human bipedal locomotion. *Nature* **369**, 645–648 (1994).
36. Wood, B. *Koobi Fora Research Project Vol. 4: Hominid Cranial Remains* (Clarendon, Oxford, 1991).
37. Broom, R. & Schepers, G. W. H. *The South African Fossil Ape-men: The Australopithecinae*. Transvaal Museum Memoir 2 (Transvaal Museum, Pretoria, 1964).

**Supplementary Information** is linked to the online version of the paper at [www.nature.com/nature](http://www.nature.com/nature).

**Acknowledgements** We thank the Authority for Research and Conservation of Cultural Heritage (ARCCH) and the National Museum of Ethiopia of the Ministry of Tourism and Culture, and the Afar regional government for permits; A. Dessie, T. Gebreselassie, G. Assefa, A. Kebede, M. Mekonnen, H. Defar, A. Zerihun, A. Takele and the people of the Dikika area for field assistance; A. Admassu for laboratory assistance; the National Geographic Society, the Institute of Human Origins at ASU and the Leakey Foundation for financial and logistical support. For discussions and help, we thank R. Ackermann, M. Clegg, H. Coqueugnot, C. Dean, T. Fitch, J.-J. Hublin, L. Humphrey, P. Jenkins, D. Johanson, K. Kupczik, S. Larson, D. Lieberman, C. Lockwood, R. Martin, E. Mbua, R. McCarthy, K. Mowbray, P. Morris, T. Nishimura, P. O'Higgins, O. Pearson, A. Pommert, Y. Rak, J. Richtsmeier, L. Scheuer, B. Sokhi, B. Viola, C. Ward and T. Weaver. We also thank B. Wood for critical comments and suggestions that have improved our paper greatly.

**Author Information** Reprints and permissions information is available at [www.nature.com/reprints](http://www.nature.com/reprints). The authors declare no competing financial interests. Correspondence and requests for materials should be addressed to Z.A. ([zera@eva.mpg.de](mailto:zera@eva.mpg.de)).